

The Anatolian Journal of Cardiology

Anatol J Cardiol • Volume 23 • Issue 1 • January 2020

Editor-in-Chief

Çetin Erol

Editor

Mustafa Kılıçkap

Advisory Board of This Issue

Tolga Reşat Aydos
 Hüseyin Ayhan
 Nihal Akar Bayram
 Hüseyin Bozbaş
 Erkan Cüre
 Çağlar Emre Çağlıyan
 Özlem Özcan Çelebi
 Hülya Çiçekçioğlu
 Abdullah Tuncay Demiryürek
 Hüseyin Ede
 Okan Erdoğan
 Nihan Kahya Eren
 Yusuf Emre Gürel
 Aysel Güven
 Erdoğan İlkay
 Ergün Barış Kaya
 Cansın Tulunay Kaya
 Ata Kırılmaz
 Serdar Küçüköğlü
 Muradiye Nacak
 Kaan Okyay
 Ercüment Ölmez
 Özcan Örşçelik
 Çağdaş Özdöl
 Alev Arat Özkan
 Nuhan Puralı
 Yıldırım Sara
 Korhan Soylu
 Dimitrios A. Stakos
 Hamza Sunman
 Erhan Tenekecioğlu
 Eralp Tutar
 Yağız Üresin
 Ertan Vuruşkan
 Tong Wang
 Ümit Yaşar
 Cafer Sadık Zorkun

Invited Review

The implications and requirements of transcatheter aortic valve replacement in low-risk patients
 Emin Murat Tuzcu and Ahmad Edris; Abu Dhabi-United Arab Emirates

Review

Non-vitamin K antagonist oral anticoagulants in cancer patients with atrial fibrillation
 Anetta Undas and Leszek Drabik; Krakow-Poland

Original Investigations

Ischemic postconditioning reduced myocardial ischemia-reperfusion injury: The roles of melatonin and uncoupling protein 3
 Gülnur Aslan et al.; Elazığ-Turkey

In-stent restenosis of drug-eluting stents in patients with diabetes mellitus: Clinical presentation, angiographic features, and outcomes
 Ganesh Paramasivam et al.; Karnataka-India

Losartan inhibits hyposmotic-induced increase of I_{Ks} current and shortening of action potential duration in guinea pig atrial myocytes
 Jie Gao et al.; Shaanxi-China

Assessment of left ventricular function in type 2 diabetes mellitus patients with non-alcoholic fatty liver disease using three-dimensional speckle-tracking echocardiography
 Yu Dong et al.; Dalian-China

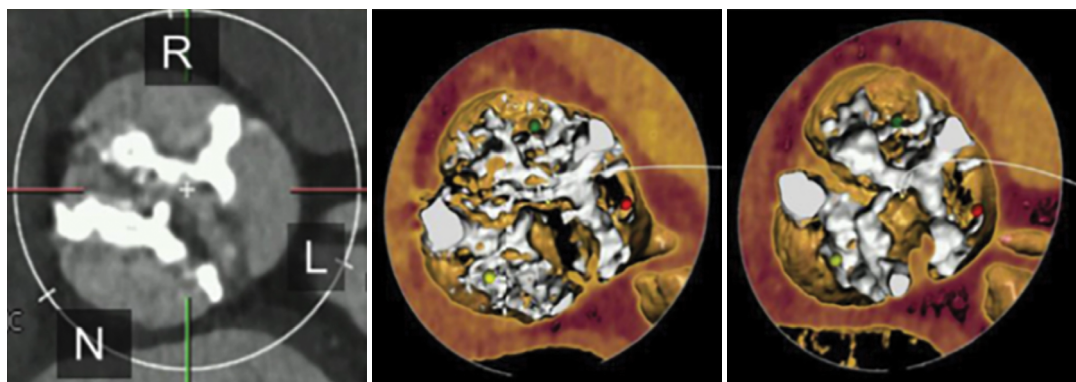
Case Reports

How to safely occlude left atrial appendage with a thrombus inside?
 Şükrü Akyüz et al.; İstanbul-Turkey

Young woman with cardiac arrest due to spontaneous coronary artery dissection
 Murat Çimci et al.; Geneva-Switzerland

Left main coronary artery occlusion by external compression with a large pulmonary artery in Eisenmenger syndrome
 İbrahim Başarıcı; Antalya-Turkey

Page: E-1



Editor-in-ChiefProf. Dr. Çetin Erol, *Ankara, Turkey***Editor**Mustafa Kılıçkap, *Ankara, Turkey***Associate Editors**

Adnan Abacı, *Ankara, Turkey*
 Rüçhan Akar, *Ankara, Turkey*
 Bülent Behlül Altunkeser, *Konya, Turkey*
 Serdal Arslan, *Sivas, Turkey*
 Ahmet Kaya Bilge, *İstanbul, Turkey*
 Hakim Çelik, *Şanlıurfa, Turkey*
 Recep Demirbağ, *Şanlıurfa, Turkey*
 Ş. Remzi Erdem, *Ankara, Turkey*
 İlkey Erdoğan, *Ankara, Turkey*
 Sadi Güleç, *Ankara, Turkey*
 Ali Gürbüz, *İzmir, Turkey*
 Serdar Kula, *Ankara, Turkey*

Selma Metintaş, *Eskişehir, Turkey*
 Kurtuluş Özdemir, *Konya, Turkey*
 Murat Özeren, *Mersin, Turkey*
 Leyla Elif Sade, *Ankara, Turkey*
 Asife Şahinarslan, *Ankara, Turkey*
 Ahmet Temizhan, *Ankara, Turkey*
 Ercan Tutar, *Ankara, Turkey*
 Omaç Tüfekçioğlu, *Ankara, Turkey*
 F. Ajlan Tükün, *Ankara, Turkey*
 Taner Ulus, *Eskişehir, Turkey*
 Aylin Yıldırım, *Ankara, Turkey*
 Mehmet Birhan Yılmaz, *İzmir, Turkey*

Editor-in-Chief Consultant
 Suna Kıraç, *Lefkoşe, KKTC*

Senior Consultant in Biostatistics
 Kazım Özdamar, *Eskişehir, Turkey*

Consultant in Biostatistics
 Fezan Mutlu, *Eskişehir, Turkey*

Previous Editor-in-ChiefBilgin Timuralp, *Eskişehir, Turkey***Editorial Board**

Ramazan Akdemir, *Sakarya, Turkey*
 Levent Akyürek, *Göteborg, Sweden*
 Azin Alizadehasl, *Tehran, Iran*
 Necmi Ata, *Eskişehir, Turkey*
 Saide Aytekin, *İstanbul, Turkey*
 Vedat Aytekin, *İstanbul, Turkey*
 Ljuba Bacharova, *Bratislava, Slovak Republic*
 Luigi P. Badano, *Udine, Italy*
 Anzel Bahadır, *Düzce, Turkey*
 Adrian Baranchuk, *Kingston, Ontario, Canada*
 Murat Biteker, *Muğla, Turkey*
 Eugene Braunwald, *Boston, MA, USA*
 Cahid Civelek, *St. Louis, MO, USA*
 Ali Emin Denктаş, *Houston, TX, USA*
 Polychronis Dilaveris, *Athens, Greece*
 Firat Duru, *Zurich, Switzerland*

Ertuğrul Ercan, *İzmir, Turkey*
 Okan Erdoğan, *İstanbul, Turkey*
 Özcan Erel, *Ankara, Turkey*
 Ali Gholamrezanezhad, *Tehran, Iran*
 Michael Gibson, *Boston, MA, USA*
 Orhan Gökbal, *İzmir, Turkey*
 Bülent Görenek, *Eskişehir, Turkey*
 Okan Gülel, *Samsun, Turkey*
 Sema Güneri, *İzmir, Turkey*
 Yekta Gürlertop, *Edirne, Turkey*
 Murat Güvener, *Ankara, Turkey*
 Cemil İzgi, *London, UK*
 Diwakar Jain, *Philadelphia, USA*
 Erdem Kaşıkçioğlu, *İstanbul, Turkey*
 Cihançir Kaymaz, *İstanbul, Turkey*
 Mustafa Kılıç, *Denizli, Turkey*

Serdar Küçüköğlü, *İstanbul, Turkey*
 Peter Macfarlane, *Renfrewshire, Scotland*
 Robert W. Mahley, *San Francisco, CA, USA*
 Giuseppe Mancina, *Milan, Italy*
 G.B. John Mancini, *Vancouver BC, Canada*
 Pascal Meier, *London, UK*
 Franz H. Messerli, *New York, USA*
 Sanem Nalbantgil, *İzmir, Turkey*
 Navin C. Nanda, *Birmingham, AL, USA*
 Yılmaz Nişancı, *İstanbul, Turkey*
 Hakan Oral, *Ann Arbor, MI, USA*
 Necla Özer, *Ankara, Turkey*
 Zeki Öngen, *İstanbul, Turkey*
 Mehmet Özkan, *İstanbul, Turkey*
 Sotirios N. Prapas, *Athens, Greece*

Fausto J. Pinto, *Lisbon, Portugal*
 Vedat Sansoy, *İstanbul, Turkey*
 Raşit Sayın, *Trabzon, Turkey*
 Mark V. Sherrid, *New York, USA*
 Horst Sievert, *Frankfurt, Germany*
 İlke Sipahi, *İstanbul, Turkey*
 Richard Sutton, *Monaco, Monaco*
 Ahmet Şaşmaz, *İstanbul, Turkey*
 S. Lale Tokgözoğlu, *Ankara, Turkey*
 Murat Tuzcu, *Cleveland, OH, USA*
 Dilek Ural, *İstanbul, Turkey*
 Ahmet Ünalır, *Eskişehir, Turkey*
 Selma Arzu Vardar, *Edirne, Turkey*
 Mehmet Yokuşoğlu, *Ankara, Turkey*
 Jose L. Zamorano, *Madrid, Spain*
 Wojciech Zareba, *New York, USA*
 Yuqing Zhang, *Beijing, China*



**TURKISH
 SOCIETY OF
 CARDIOLOGY**

**The Owner on behalf of
 the Turkish Society of Cardiology**

**Türk Kardiyoloji Derneği adına
 İmtiyaz Sahibi**

Mustafa Kemal EROL

Address : Nish İstanbul A Blok Kat: 8, No: 47-48

Çobançesme Sanayi Cad. No: 11

Yenibosna, Bahçelievler 34196

İstanbul, Türkiye

Phone : +90 212 221 1730-38

Fax : +90 212 221 1754

E-mail : tkd@tkd.org.tr

Web : www.tkd.org.tr

Editor-in-Chief Office

Phone : +90 (535) 461 41 62

Fax : +90 (212) 221 17 54

E-mail : info@anatoljcardiol.com

Assistants to the Editor-in-Chief

Ebru BOZ

Elif SÖNMEZ



Publisher: Kare Yayıncılık (Kare Publishing)

Concord İstanbul Dumlupınar Mah. Yumurtacı Abdi Bey
 Cad. Cihan Sok. No: 15, B Blok Da: 162 Kat: 21, Kadıköy,
 İstanbul, TURKEY

Phone: +90 216 550 61 11

Fax: +90 216 550 61 12

<http://www.kareyayincilik.com>

E-mail: kareyayincilik@gmail.com

Yayın Türü: Uluslararası Süreli, Basım Tarihi: Ocak 2020

Basım: Filmevi Grafik Renk Ayrımı Sistemleri San.

Tic. LTD. ŞTİ. İstanbul-Türkiye

CONTENTS

EDITORIAL

- ▶ TAVR, NOACs, NAFLD, and a Happy New Year 1
Çetin Erol; Ankara-Turkey

INVITED REVIEW

- ▶ The implications and requirements of transcatheter aortic valve replacement in low-risk patients 2
Emin Murat Tuzcu, Ahmad Edris; Abu Dhabi-United Arab Emirates

REVIEW




- ▶ Non-vitamin K antagonist oral anticoagulants in cancer patients with atrial fibrillation 10
Anetta Undas, Leszek Drabik; Krakow-Poland

ORIGINAL INVESTIGATIONS

- ▶ Ischemic postconditioning reduced myocardial ischemia-reperfusion injury: The roles of melatonin and uncoupling protein 3 19
Gülner Aslan, Hüseyin Fatih Gül, Ahmet Tektemur, Engin Şahna; Elazığ-Turkey
- ▶ In-stent restenosis of drug-eluting stents in patients with diabetes mellitus: Clinical presentation, angiographic features, and outcomes 28
Ganesh Paramasivam, Tom Devasia, Ashwal Jayaram, Abdul Razak, M. Sudhakar Rao, Rajesh Vijayvergiya, Krishnananda Nayak; Karnataka, Chandigarh-India
- ▶ Losartan inhibits hyposmotic-induced increase of I_{Ks} current and shortening of action potential duration in guinea pig atrial myocytes 35
Jie Gao, Tian Yun, Xiao-Lu Xie, Jin Zhao, Chuan-hao Liu, Ying Sheng, Fang Cao; Shaanxi-China
- ▶ Assessment of left ventricular function in type 2 diabetes mellitus patients with non-alcoholic fatty liver disease using three-dimensional speckle-tracking echocardiography 41
Yu Dong, Dongmei Huang, Lihua Sun, Ying Wang, Ying Li, Wenxing Chang, Guangsen Li, Hongyan Cui; Dalian-China

CONTENTS



CASE REPORTS

- ▶ How to safely occlude left atrial appendage with a thrombus inside?  49
Şükrü Akyüz, İlhan İlker Avcı, Can Yücel Karabay, Duygu Genç, Ali Palice; İstanbul-Turkey
- ▶ Young woman with cardiac arrest due to spontaneous coronary artery dissection  53
Murat Çimci, Tornike Sologashvili, Nurcan Yılmaz, Caroline Frangos, Marco Roffi; Geneva-Switzerland
- ▶ Left main coronary artery occlusion by external compression with a large pulmonary artery in Eisenmenger syndrome  55
İbrahim Başarıcı; Antalya-Turkey

LETTERS TO THE EDITOR

- ▶ Measurement of salusin-β without the addition of NP-40 or Tween-20 in coronary slow-flow phenomenon 57
Suna Aydın, Meltem Yardım, Ramazan Fazıl Akkoç; Elazığ-Turkey
- ▶ Perivascular adipose tissue in cardiovascular diseases 58
Niki Katsiki, Dimitri P. Mikhailidis; Thessaloniki-Greece, London-United Kingdom

E-PAGE ORIGINAL IMAGES

- ▶ Visualization of exceptional cross-sectional en-face views of pulmonary and tricuspid valves using 2D transthoracic echocardiography in patients with pulmonary hypertension  E-1
İbrahim Başarıcı; Antalya-Turkey
- ▶ Biventricular outflow obstruction in a patient with a large sinus of the Valsalva aneurysm  E-2
Zahra Khajali, Melody Farrashi, Alireza Alizadeh Ghavidel, Mozhgan Parsaee; Tehran-Iran